

Mr KL, Age 58

- R hand dominant, support worker, lives in West Lothian
- Date of injury: 28/07/18
- Mechanism of injury: Tripped, fall from own height
- Injury: Anterior shoulder dislocation with greater tuberosity fracture, reduced in A&E. # Managed conservatively

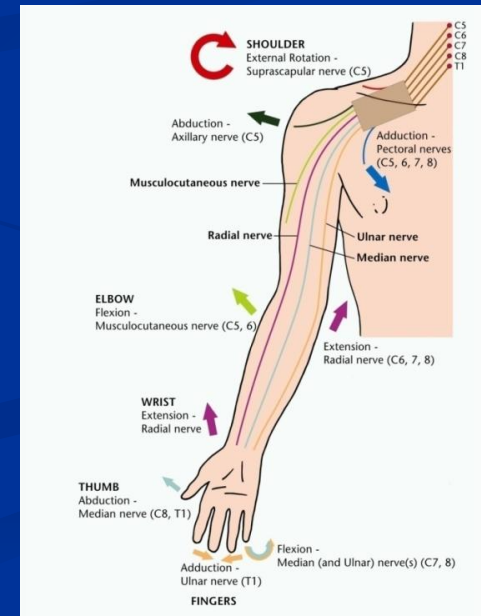
Date: 03/09/18

Mr KL: Muscle powers

Trapezius	5
Serratus anterior	5
Supra/Infraspinatus	4
Deltoid	4
Pectoralis major	5
Lat dorsi	5
Biceps	0
Triceps	4
Wrist extension	0
EDC	0
FCR	0
FDP/FDS	0
FPL	0
Ulnar Intrinsic	0
Thenar muscles	0

Sensory Assessment

C5	Absent
C6	Absent
C7	Absent
C8	Absent
T1	Absent



Mr ? : Investigations

- **X-rays?** Shoulder reduced successfully and minimally displaced GT #
- **MRI?** Nil
- **Neurophysiology :** Nil

Mr KL: Non-Operative treatment.

■ **Physiotherapy:**

- Initial contact at clinic appt, nothing arranged locally yet.
- Education
- Commenced passive stretches and active shoulder ROM
- Resting hand splint
- Referred to local PT

■ **Occupational therapy:**

- Assessment of function and provision of small aids to assist
- Follow up telephone call

■ **Nurse Specialist**

- Pain management discussion and telephone call to GP surgery to review medication
- Ongoing monitoring of mood and coping strategies/ need for support